

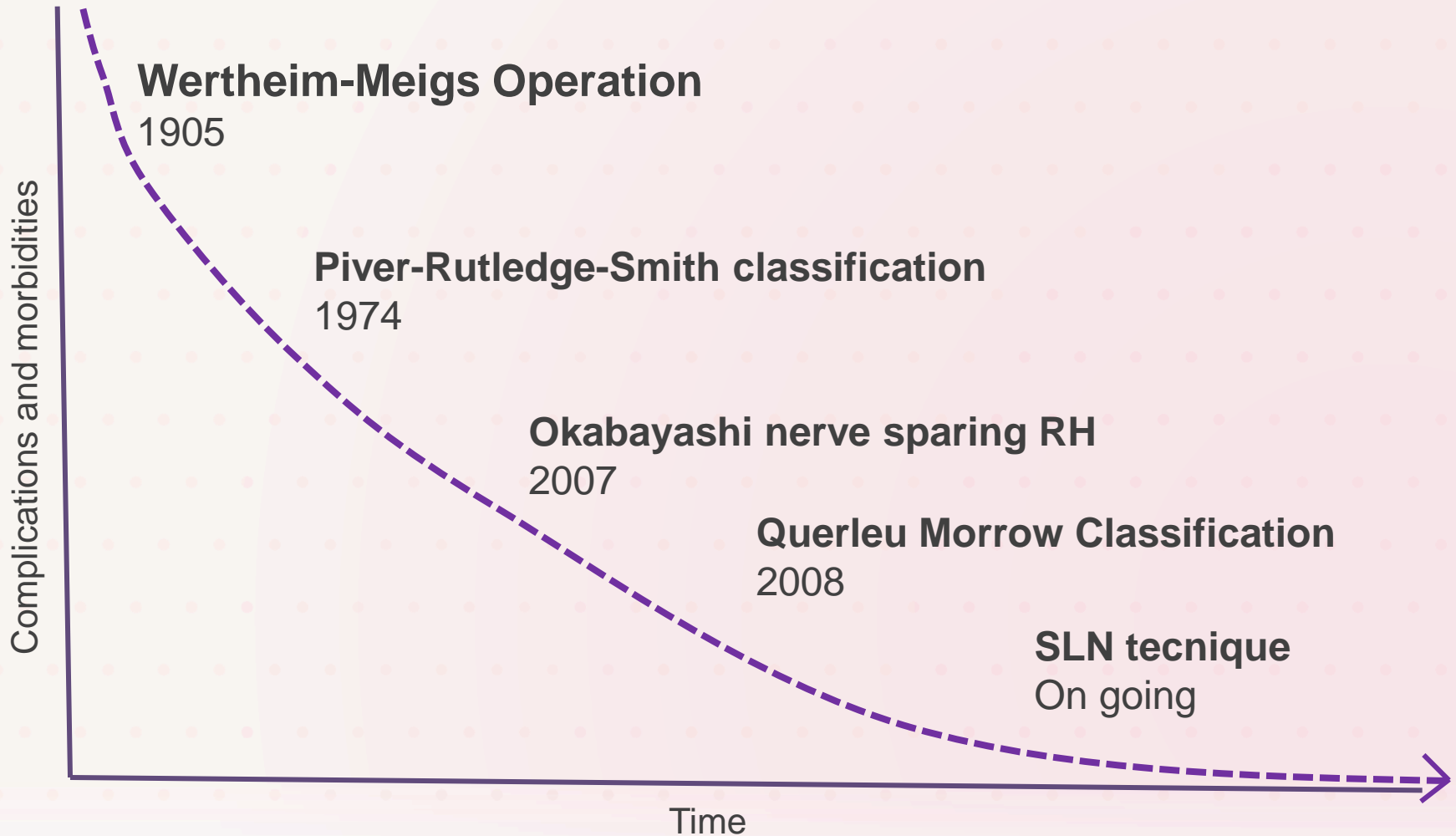
# EVOLUTION OF RADICALITY IN CC

***Prof. Franco Odicino***

***Divisione di Ostetricia e Ginecologia - Spedali Civili di Brescia***

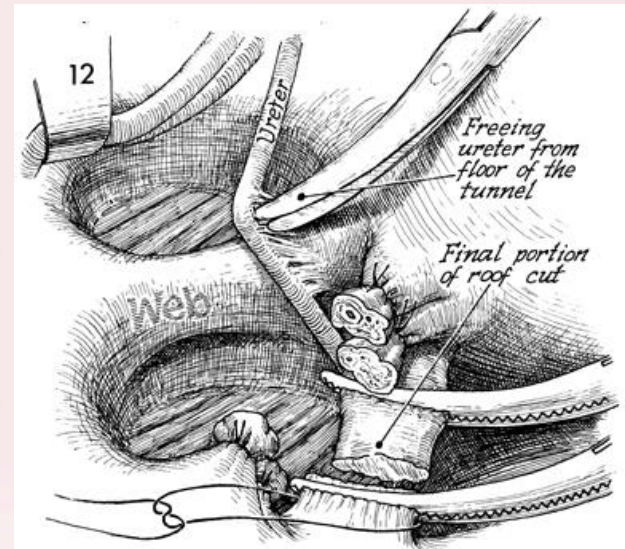
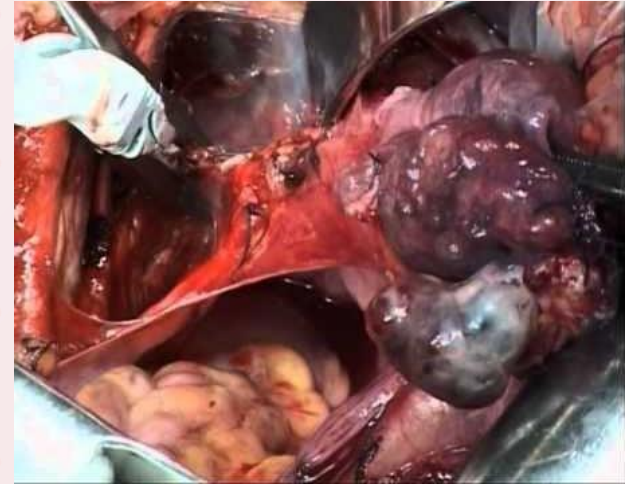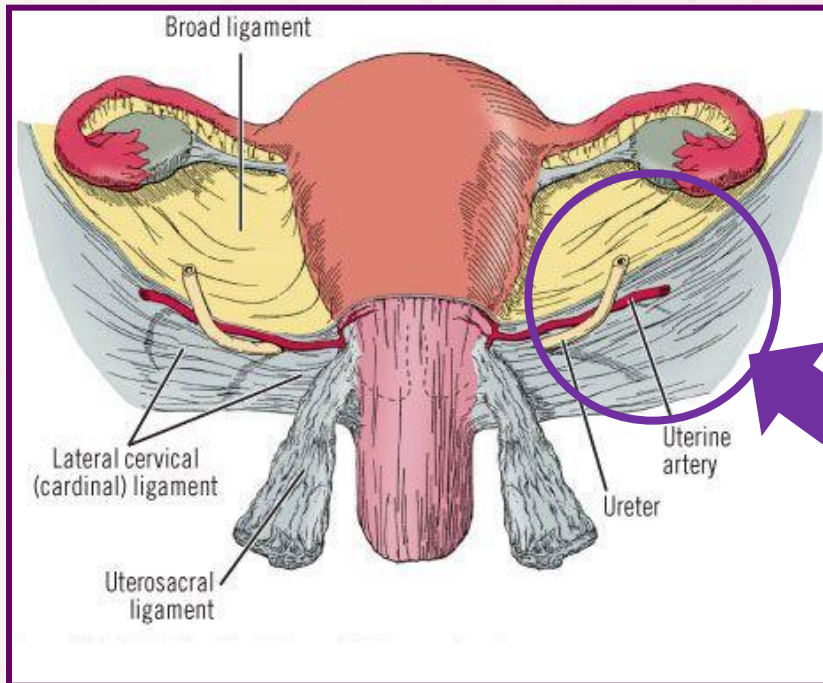
# RADICAL HYSTERECTOMY

- Shifting paradigm from the 19th century



# WERTHEIM-MEIGS OPERATION, 1905

- What is “radical”?
- Very aggressive surgery!
- High rate of complications!!



# PIVER-RUTDLEGE-SMITH CLASSIFICATION

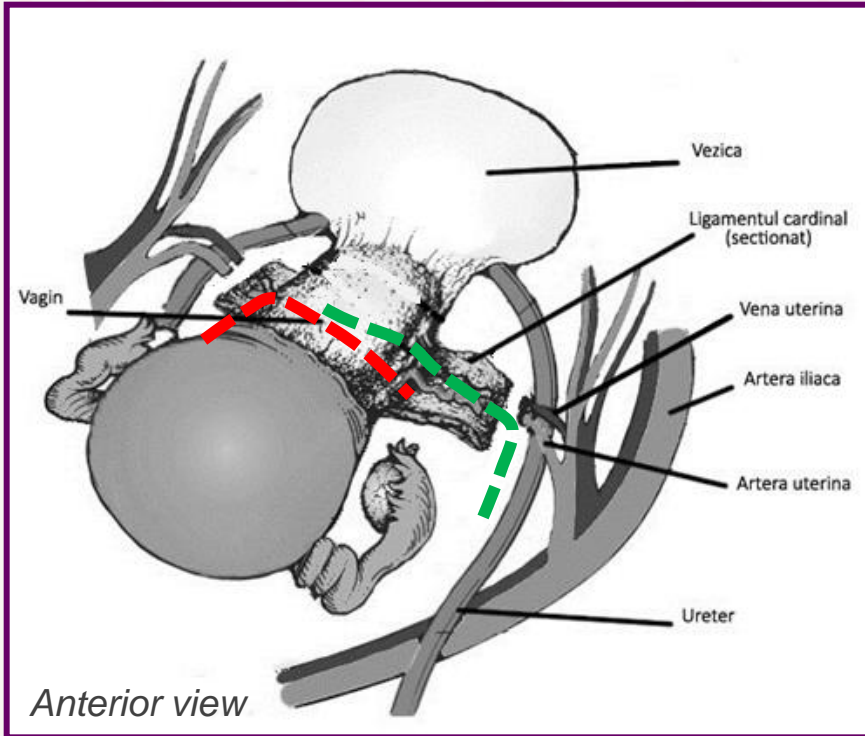
## Since 1974, type III RH

Considered worldwide by many as the standard surgical therapy for invasive cervical carcinoma stage IB and IIA

## Classification of the radicality of the procedure

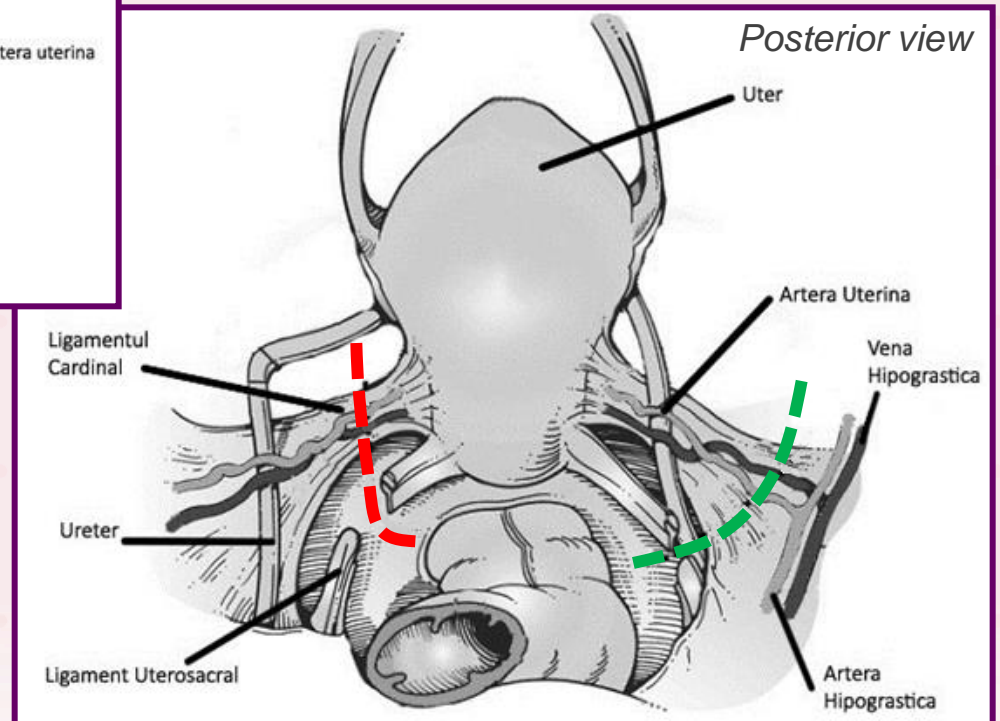
- **Class I**  
Simple extrafascial hysterectomy
- **Class II**  
Modified radical hysterectomy
- **Class III**  
Radical hysterectomy
- **Class IV**  
Radical hysterectomy, removal of  $\frac{3}{4}$  of vagina, sacrifice of umbilical artery and complete dissection of pubovesical ligament
- **Class V**  
Excision of distal ureter and bladder

# DIFFERENCE BETWEEN CLASS II AND CLASS III

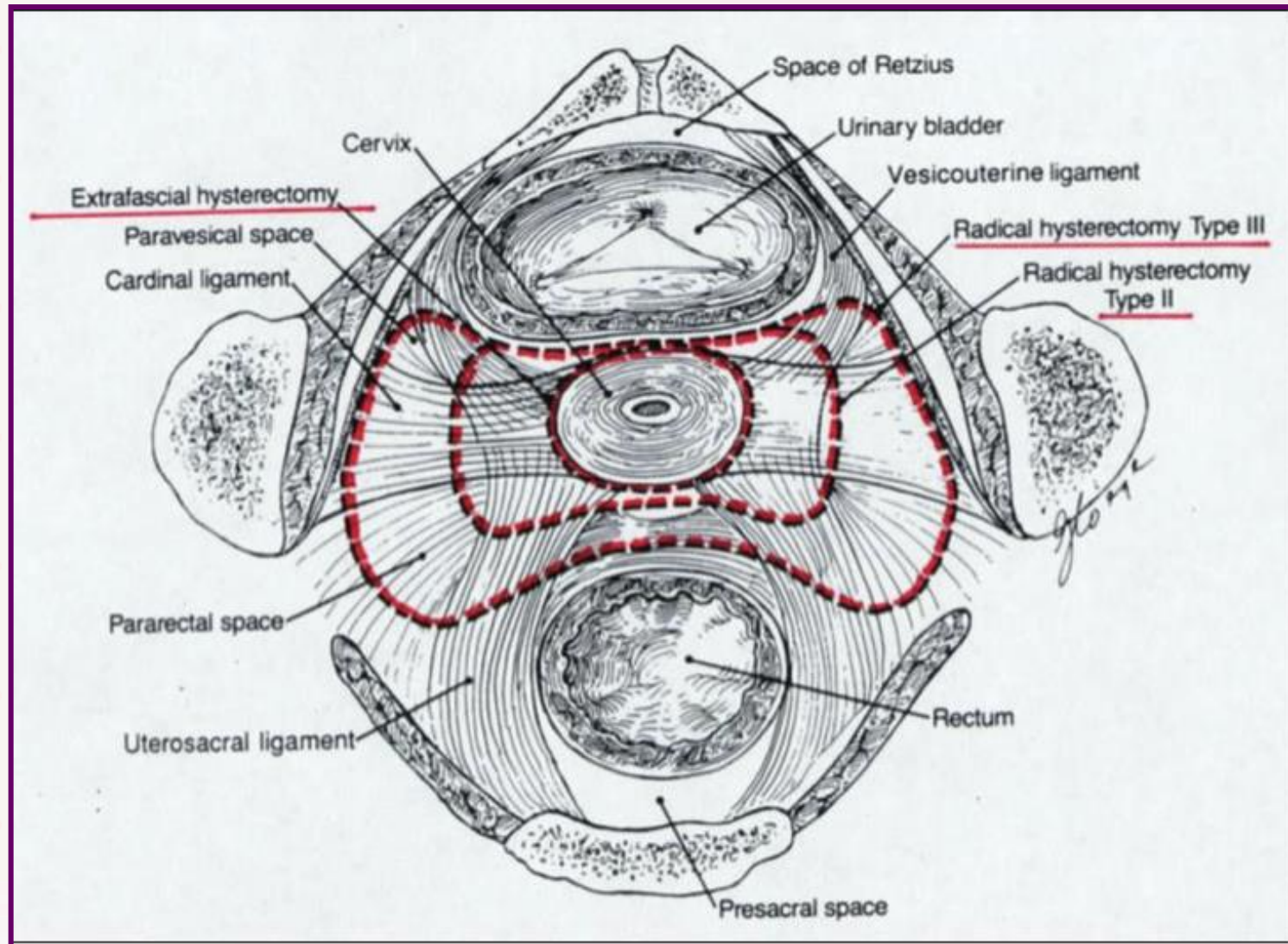


**Modified Radical Hysterectomy, class II**

**Radical Hysterectomy, class III**



# DIFFERENCE BETWEEN CLASS II AND CLASS III



# NERVE SPARING

## Anatomic identification and functional outcomes of the nerve sparing Okabayashi radical hysterectomy

Shingo Fujii \*, Kenji Takakura, Noriomi Matsumura, Toshihiro Higuchi, Shigeo Yura,  
Masaki Mandai, Tsukasa Baba, Shinya Yoshioka

*Department of Gynecology and Obstetrics, Postgraduate School of Medicine, Kyoto University, Sakyo-ku, Kyoto, 606-8507, Japan*

Received 27 June 2007

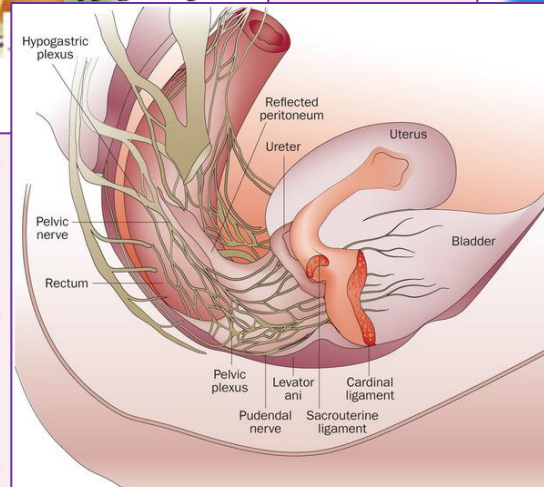
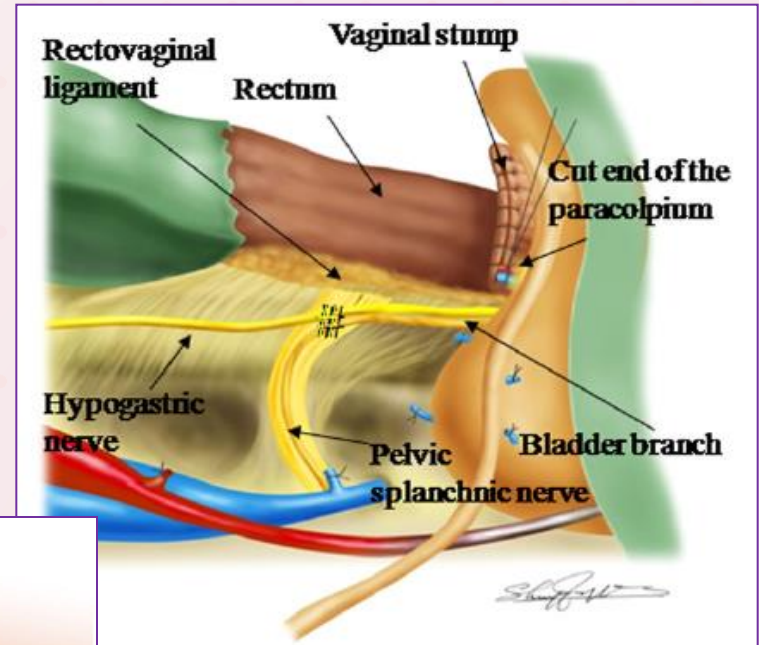
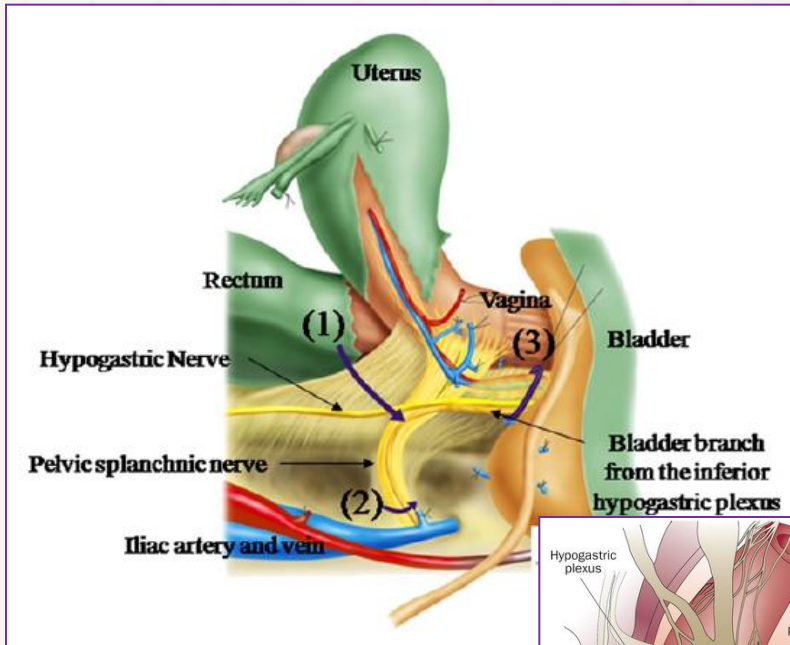
- **Parametrial resection**

Transection of hypogastric nerves with alteration of normal voiding function

- **Spare nervous fibers without reduced oncological safety**

**Nerve Sparing approach reduced the problems, but anatomy is very complex and various...**

# NERVE SPARING



**Nerve Sparing approach reduced the problems, but anatomy is very complex and various...**